

Alectinib-induced haemolytic anaemia in anaplastic lymphoma kinase–positive non–small-cell lung cancer: a case report

Toby CH Leung*, MB, ChB, Tommy CY So, MB, BS, FHKAM (Radiology)

Department of Clinical Oncology, Pamela Youde Nethersole Eastern Hospital, Hong Kong SAR, China

* Corresponding author: lch423@ha.org.hk

This article was published on 14 Oct 2024 at www.hkmj.org.

Hong Kong Med J 2024;30:Epub
<https://doi.org/10.12809/hkmj2311077>

This version may differ from the print version.

Case presentation

A 70-year-old Chinese woman was diagnosed with stage IV anaplastic lymphoma kinase (ALK)–positive non–small-cell lung carcinoma with intrapulmonary, pleural and lymph node metastasis

in December 2022. Her private oncologist first prescribed lorlatinib in mid-December 2022. The drug had been well tolerated by the patient and there was no evidence of myelotoxicity.

The patient attended a public hospital for further care in February 2023. Lorlatinib was switched to alectinib on 17 March 2023. Her baseline haemoglobin level was 11.1 g/dL on 16 March 2023 prior to commencement of alectinib. Subsequent follow-ups on 13 April and 3 May revealed that her haemoglobin level had fallen to 10 g/dL and 8.7 g/dL, respectively (Fig 1a). Mean cell volume was 65.4 fL. She had no clinical signs or symptoms suggestive of acute blood loss.

Peripheral blood smear showed marked red cell spherocytosis (Fig 2). The previously normal bilirubin level rose to 43 µmol/L and lactate dehydrogenase (LDH) level to 317 IU/L. Haptoglobin level was very low (<0.06 g/L) [Fig 1b]. Direct Coombs test (DAT) was negative. Alectinib had been withheld since 3 May 2023 in view of the potential differential diagnosis of drug-induced haemolytic anaemia. After suspending alectinib, the haemoglobin level remained static for 1 week (8.7 g/dL on 10 May 2023). It then increased slowly over the following week (9.1 g/dL on 15 May 2023) [Fig 1a]. Lactate dehydrogenase level also decreased to 278 IU/L, with total bilirubin level decreased to 24 µmol/L and direct bilirubin level normalised (Fig 1b).

Since the anaemia of the patient had improved, another ALK inhibitor, brigatinib, was prescribed on 18 May 2023, at 90 mg daily. Her haemoglobin level increased to 9.7 g/dL after 2 weeks. Total bilirubin level was normalised on 1 June 2023 (Fig 1a). Brigatinib was then stepped up to 180 mg daily (full dose) as it was well tolerated.

The patient demonstrated a favourable response to ALK inhibitors as evidenced by a continuously decreasing cancer embryonic antigen level. A contrast computed tomography scan of the thorax, abdomen and pelvis on 30 May 2023 showed partial response after 5 months of lorlatinib and alectinib. The primary lung tumour at the right lower lobe showed a partial response, decreasing from

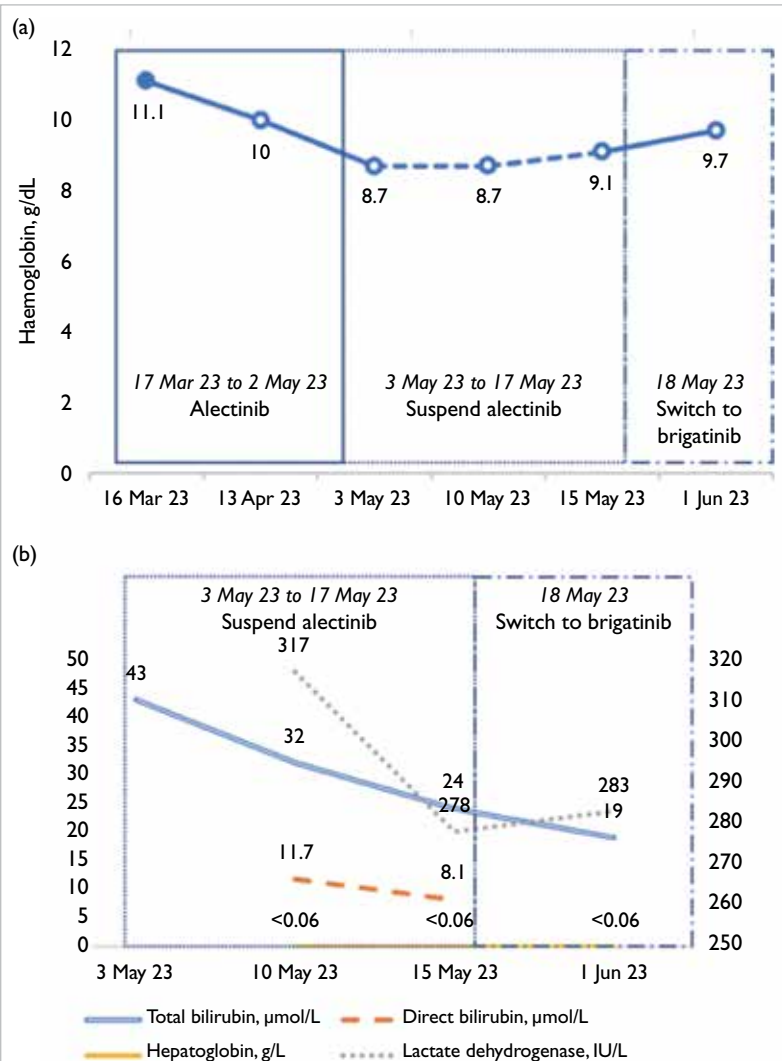


FIG 1. (a) Temporal relationship between haemoglobin level and the use of different anaplastic lymphoma kinase inhibitors. (b) Trend of different biochemical markers related to haemolytic anaemia

6.2 cm to 1.5 cm in size. There was no evidence of bone metastasis.

Discussion

Anaemia caused by alectinib is uncommon although clinical trials have reported clinically significant anaemia (grade ≥ 3) in around 7% of cases.¹ Nonetheless there are limited reports of alectinib-induced haemolytic anaemia.² Misawa et al³ described a case of grade 4 anaemia due to drug-induced haemolytic anaemia in 2023. No such case has been reported in Hong Kong to date.

The index patient demonstrated alectinib-induced haemolytic anaemia with morphological change to erythrocytes and negative DAT result. The blood smear of spherocanthocytosis combined with altered bilirubin, LDH and haptoglobin was strongly suggestive of haemolytic anaemia. The improvement in haemoglobin, bilirubin and LDH levels following suspension of alectinib suggested that the haemolytic anaemia was drug induced.

Drug-induced haemolytic anaemia is usually due to drug-induced immune haemolytic anaemia.⁴ Nonetheless in this case, an autoimmune cause was excluded due to the patient's negative DAT result even though 5% to 10% of DAT-negative cases may have an immune component.² Differential diagnoses of DAT-negative haemolytic anaemia include membranopathies (eg, hereditary spherocytosis), thrombotic microangiopathies (eg, thrombotic thrombocytopenic purpura), enzymopathies (eg, glucose-6-phosphate dehydrogenase), infection (eg, malaria or *Clostridium*), and haemoglobinopathies (eg, sickle cell disease).⁵ Our patient had no signs of infection or history of haematological disease. The temporal relationship between administration of alectinib and the occurrence of haemolytic anaemia favoured a diagnosis of drug-induced haemolysis.

The laboratory findings were also consistent with other case reports.⁶

The precise mechanism is uncertain. It has been postulated that alectinib induces erythrocyte membrane changes.³ The presence of spherocytes in the peripheral blood film may arise from these membrane changes (Fig 2). Additional investigation is warranted to further understand the underlying mechanism.

Our patient developed haemolytic anaemia within 2 months of commencing alectinib. Misawa et al³ reported that grade 4 haemolytic anaemia could occur after 3 years. Regular monitoring of haemoglobin should be undertaken in patients prescribed alectinib. Haemolytic anaemia workup, including peripheral blood smear, bilirubin, haptoglobin and LDH levels, should be considered if indicated.

This case demonstrated no cross reactivity among other ALK-positive first-line targeted therapies (lorlatinib and brigatinib). Our patient first commenced lorlatinib following a private consultation and later switched to alectinib with funding support. The patient continues her treatment with brigatinib. There was no documented drop in haemoglobin level after lorlatinib, and following discontinuation of alectinib and initiation of brigatinib, her haemoglobin level showed an improving trend. Limited case reports of alectinib-induced haemolytic anaemia have been managed by discontinuation of therapy or rechallenge with alectinib at a reduced dosage.^{2,3,6} To the best of our knowledge, cross reactivity among first-line ALK tyrosine inhibitors (lorlatinib, alectinib and brigatinib) has not been reported. Our case demonstrates that it is safe to switch treatment to an alternative ALK inhibitor when alectinib-induced haemolytic anaemia occurs. The drug-induced haemolytic anaemia is specific to alectinib.

Conclusion

This case highlights the importance of interval haemoglobin monitoring. A persistent drop in haemoglobin level following initiation of alectinib warrants prompt investigations for possible differential diagnosis of alectinib-induced haemolytic anaemia. This case also suggests that it is safe to switch to an alternative ALK inhibitor in the presence of alectinib-induced haemolytic anaemia.

Author contributions

Both authors contributed to the concept or design of the study, acquisition of the data, analysis or interpretation of the data, drafting of the manuscript, and critical revision of the manuscript for important intellectual content. Both authors had full access to the data, contributed to the study, approved the final version for publication, and take responsibility for its accuracy and integrity.

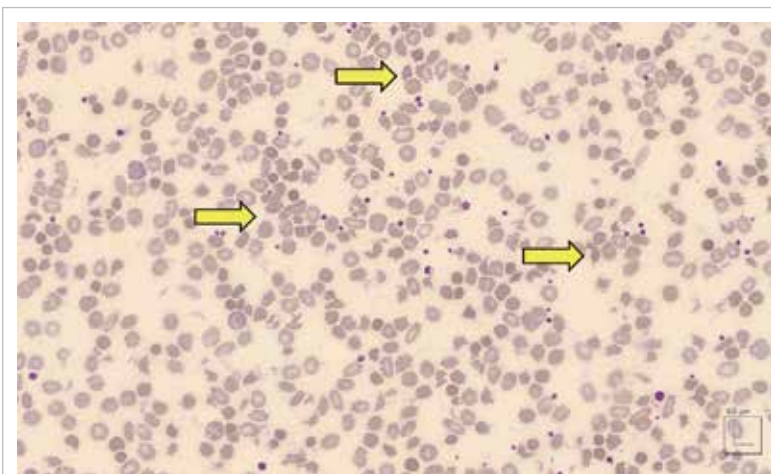


FIG 2. Peripheral blood smear showing spherocanthocytosis of red cells (yellow arrows) [Wright-Giemsa stains, $\times 1000$]

Conflicts of interest

Both authors have disclosed no conflicts of interest.

Acknowledgement

The authors thank Dr Kenneth Mung from the Department of Pathology of Pamela Youde Nethersole Eastern Hospital for providing microscopic photos of the blood smear of the patient.

Funding/support

This study received no specific grant from any funding agency in the public, commercial, or not-for-profit sectors.

Ethics approval

The patient was treated in accordance with the Declaration of Helsinki. The patient provided consent for all treatments and procures, and consent for publication of this case report.

References

1. Mok T, Camidge DR, Gadgeel SM, et al. Updated overall survival and final progression-free survival data for patients with treatment-naive advanced ALK-positive non-small-cell lung cancer in the ALEX study. *Ann Oncol* 2020;31:1056-64.
2. Okumoto J, Sakamoto S, Masuda T, et al. Alectinib-induced immune hemolytic anemia in a patient with lung adenocarcinoma. *Intern Med* 2021;60:611-5.
3. Misawa, K, Nakamichi S, Iida H, et al. Alectinib-induced severe hemolytic anemia in a patient with ALK-positive non-small cell lung cancer: a case report. *Onco Targets Ther* 2023;16:65-9.
4. Garbe E, Andersohn F, Bronder E, et al. Drug induced immune haemolytic anaemia in the Berlin Case-Control Surveillance Study. *Br J Haematol* 2011;154:644-53.
5. Palmer D, Seviar D. How to approach haemolysis: haemolytic anaemia for the general physician. *Clin Med (Lond)* 2022;22:210-3.
6. Gullapalli V, Xu W, Lewis CR, Anazodo A, Gerber GK. A multi-centre case series of alectinib-related erythrocyte membrane changes and associated haemolysis. *J Hematop* 2021;14:131-6.

1. Mok T, Camidge DR, Gadgeel SM, et al. Updated overall