

FSM Ting
AKH Kwok 郭坤豪

Treatment of epiretinal membrane: an update

治療視網膜前膜病變的跟進報告

Epiretinal membrane is a common surgical disease of the elderly. The aetiology, clinical presentation, and diagnosis are briefly described. Management, principally vitrectomy and membrane removal, is then elaborated. Recent advances such as internal limiting membrane peeling are further discussed. The safety and efficacy of intra-ocular dyes, including indocyanine green and trypan blue, as well as the new technique of 'double staining', are evaluated.

視網膜前膜病變是長者常見的外科疾病。本報告先簡述其病因、臨床表徵和診斷，然後詳細探討主要以玻璃體及視網膜切除術的治療方法，並討論一些新技術如視網膜內界膜剝除術，以及評估使用眼內染色劑如吲哚菁綠或錐蟲藍，和新技術「雙重染色法」的安全和效用。

Introduction

Epiretinal membrane (ERM), first described in 1865, is an avascular, fibrocellular membrane that proliferates on the inner surface of the retina and produces various degrees of visual impairment (Fig 1). Although peripheral ERMs can exist, macular ERMs are more visually disturbing. This discussion will be restricted to macular ERMs. The prevalence of macular ERMs is 2% in individuals under the age of 60 years and 12% in those over 70 years.¹ There are many synonyms describing this condition: macular pucker, epimacular proliferations, preretinal macular fibrosis, epiretinal fibrosis or gliosis, surface wrinkling retinopathy, and cellophane maculopathy.

Aetiology

Epiretinal membrane may be idiopathic and found in otherwise healthy eyes, or secondary. In the latter, they are associated with posterior vitreous detachment (PVD), retinal breaks, vascular retinopathy, ocular inflammation, some congenital conditions, and intra-ocular surgery such as post-retinal detachment repair, cataract repair, retinal laser, and cryotherapy.² Idiopathic ERMs have been said to be associated with diabetes mellitus, even in the absence of other ocular complications.¹

Epiretinal membranes comprise glial cells, retinal pigment epithelial (RPE) cells, macrophages, fibrocytes, and collagen fibres.^{2,3} Different proportions of these components are associated with a different aetiology. Bilateral eye involvement has been reported in 31% of cases. In an affected individual, the unaffected eye has a 2.5 times higher risk of being affected than a single eye in an unaffected individual. This suggests a systemic cause for ERM, for example, ageing or diabetes.¹ Posterior vitreous detachment, often associated with ERM, is also commonly found bilaterally.²

Key words:

Epiretinal membrane;
Indocyanine green;
Treatment outcome;
Vitrectomy

關鍵詞：

視網膜前膜；
吲哚菁綠；
治療結果；
玻璃體摘除術

Hong Kong Med J 2005;11:496-502

Department of Ophthalmology, Hong Kong Sanatorium and Hospital, Happy Valley, Hong Kong
FSM Ting
AKH Kwok, MD, FHKAM (Ophthalmology)

Correspondence to: Dr AKH Kwok
(e-mail: alvinkwok@hksh.com)

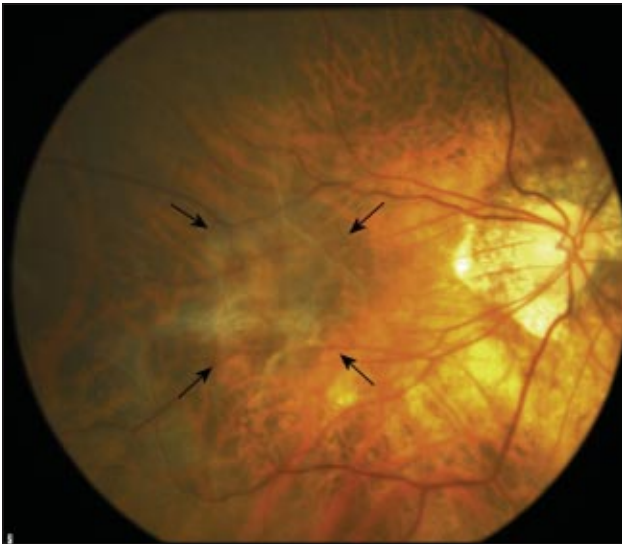

Fig 1. Fundus photograph of a myopic eye with an idiopathic epiretinal membrane (arrows)

Clinical presentation

Epiretinal membrane is symptomatic only if the macular or peri-macular area is involved. Most other cases are asymptomatic. The most common presenting symptoms are decreased visual acuity and metamorphopsia. Other symptoms include micropsia, macropsia, and monocular diplopia. The severity of symptoms is related to the area of involvement and the thickness of ERM. They follow a variable course: most will have static or slow progression.⁴ In the Blue Mountains Eye Study of Australia,² one quarter of membranes regressed or became undetectable after 5 years. Occasionally, the membrane may spontaneously detach from the retina and thereby improve symptoms.

Diagnosis

The fundus can be examined ophthalmoscopically or with a fundus photograph. An ERM is seen as a glistening light reflex if it is thin, or as an obvious transparent, translucent, or even pigmented membrane. Retinal changes are observable as surface wrinkling, vasculature distortion, cystoid macular oedema or pseudohole. Fundus photographs with a blue filter may enable very thin ERM to be identified more easily.⁵ These membranes have been classified into three grades: grade 1, cellophane membrane causing irregular wrinkling of the inner retina, no edge of ERM elevated; grade 2, more substantial ERM with full-thickness retinal distortion, edge of ERM elevated, less than half of ERM is opaque causing obscuration of underlying retina and vasculature; and grade 3, thick

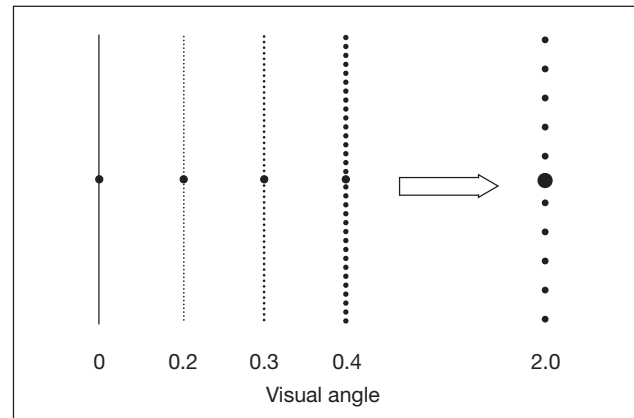


Fig 2. Demonstration of M-charts with different dot intervals

The minimum visual angle of the dotted lines needed to cause the metamorphopsia to disappear is the metamorphopsia angle. The fixation point is located at the centre of each line

opaque membrane with at least half of the ERM opaque, causing marked obscuration and distortion of the underlying retina and vasculature.⁶

The Watzke Allen test can differentiate between a pseudohole that looks like a macular hole due to an overlying ERM and a true macular hole that has a macular defect. When in doubt, examination under a slit lamp with 90D lens or 3-mirror-lens reveals the distorted inner retina at the base of a pseudohole. Fluorescein angiography can aid diagnosis. A true hole may show a window defect but a pseudohole will not. Optical coherence tomography (OCT) is also useful to help differentiate the two. Additionally, OCT images that show the retinal base thickness can predict the clinical macular function. If the retinal base is abnormally thick or thin, or irregular, visual acuity of the eye is significantly lower.⁷

Visual acuity and degree of metamorphopsia can be measured to quantify the symptoms. Visual acuity can be conveniently measured by a Snellen chart and the degree of metamorphopsia by Amsler grid or M-charts. The Amsler grid is the traditional method to document metamorphopsia. M-charts have also been used to quantify metamorphopsia and are more sensitive and better accepted by patients (Fig 2). They have 19 kinds of dotted lines with dot intervals of between 0.2° and 2.0° visual angles. At first, a vertical straight line (0°) on the first page of M-charts is shown to patient and he/she is asked to fixate on the centre fixation point of the line. If the patient recognises the straight line as straight, the metamorphopsia score is 0. If he/she recognises the straight line as irregular

or curved, the next pages of M-charts with the dotted lines changing from fine to coarse are shown in succession to the patient. When the patient recognises a dotted line as straight, its visual angle is considered his/her metamorphopsia score. Scores range from 0 to 2.0. The M-charts can be rotated 90° and the horizontal lines used to measure metamorphopsia in the horizontal axis.⁸ Different degrees of metamorphopsia exist in different patients with the same visual acuity. They are not directly related. This suggests that the degree of metamorphopsia may show some new clinical information apart from that demonstrated by visual acuity alone. The use of more sensitive and repeatable M-charts may shed more light on the relationship between preoperative and postoperative metamorphopsia.⁸

Management

Other causes of vision loss must be carefully excluded. Surgical removal of the membrane in patients with significant symptoms will improve visual acuity and reduce metamorphopsia in most cases. In other patients, visual acuity may improve less than metamorphopsia. It has not been customary to treat patients with mild and non-progressive symptoms since results are generally unsatisfactory. Nonetheless, advances in surgery and instrumentation now allow patients with relatively good visual acuity but significant metamorphopsia to be offered a choice of surgery. Grade 1 ERM may cause significant metamorphopsia with relative sparing of visual acuity. Early surgical removal can relieve the disturbing symptom and stabilise the vision that may worsen later.⁶ Surgery involves pars plana subtotal vitrectomy, removal of ERM, and peeling of the internal limiting membrane (ILM). Different methods of peeling, staining, and the extent of adjunctive ILM peeling have been described.⁹⁻¹⁸

Vitrectomy

When subtotal vitrectomy is performed, the risks of intra-operative lens damage and peripheral retinal tear are reduced. In many cases, PVD has occurred. If the posterior hyaloid is adherent to the retina, PVD should be induced. Accelerated cataract is a common complication after vitrectomy: a combination of cataract surgery and ERM has been suggested.¹⁹ Nonetheless, phacoemulsification, which is performed first, can produce corneal epithelial oedema especially in eyes with significant cataract. This may obscure the surgeon's view during subsequent ERM surgery.¹⁹ With modern cataract surgery, corneal oedema is seldom severe enough to warrant separate surgery for posterior vitrectomy and the corneal epithelium can

be scrapped to get a clearer view if needed. Another method that prevents postoperative nuclear sclerosis is non-vitreotomising vitreous surgery.²⁰ A fibreoptic light source and a microhooked needle are introduced through two sclerotomy sites. Without cutting of vitreous or other intra-ocular manoeuvres, the membrane is separated from the retina. The membrane can then be left floating in the vitreous cavity or grasped by microforceps and pulled through a sclerotomy site. Postoperative cataract is significantly reduced, with equally satisfactory visual outcomes. Although there is a risk that patients with membrane left in the vitreous cavity will complain of floaters, the condition will improve with time and the difference is insignificant compared with that in patients in whom the membrane is removed.

Membrane removal

After vitrectomy, the edge of the membrane is searched. A bent-tip needle or a vitreoretinal pick is used to lift it up. Subsequent peeling is completed with forceps. If there is no obvious edge, a cut is made at the centre of the membrane using a microvitreoretinal blade. An edge is created and forceps are used to lift off the membrane. Diamond-tipped forceps can be used in peeling so the membrane has less chance of slipping off the instrument, especially in silicone oil medium.²¹

Indocyanine green-assisted peeling

Indocyanine green (ICG) is a tricarboyanine dye, first used in ophthalmology in 1970 in choroidal angiography (Fig 3). It was later used to stain the anterior capsule during capsulorhexis. In 2000, Kadonosono et al⁹ suggested its use in staining ILM in macular hole surgery. Its safety and efficacy in macular hole surgery of senior and highly myopic patients were subsequently reported.¹⁰⁻¹³ Indocyanine green is hydrophilic and the acellular collagen of the ILM is stained positively. In contrast, cellular ERM is stained negatively. It provides a 'negative staining'. The general view of ophthalmic surgeons is that ICG improves visualisation of ILM and helps distinguish ERM. This may make the surgery safer and faster, and light toxicity to the retina is decreased. Retinal damage by unnecessary picking to search for the edge of ERM is also minimised.^{14,22} Nevertheless ICG may have a photosensitising effect on the retina and hence increase phototoxicity.^{23,24} The lowest possible concentration should be used to visualise the ERM. Different concentrations of ICG provide different staining properties. The minimum concentration of ICG should be 0.125% when used to stain the ILM under air.⁶ Only at this concentration can all ILM be satisfactorily

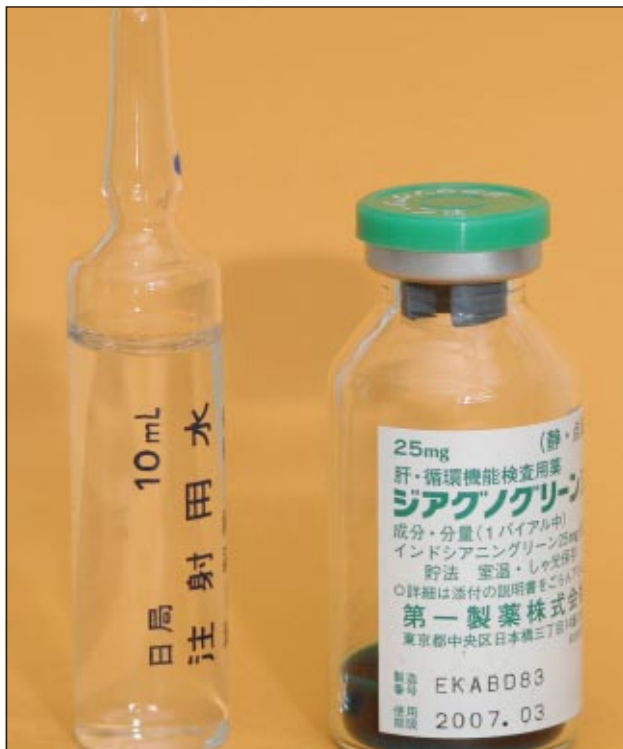

Fig 3. A bottle of indocyanine green dye with its solvent

stained in green and completely removed without the need for second staining.

Internal limiting membrane peeling is commonly adopted in macular hole surgery, but its effect on ERM surgery is uncertain.⁹⁻¹³ The presence of long segments of ILM within the histopathological specimen appears to indicate a less favourable visual outcome.²⁵ Recurrence of ERM is also possible at the margins of ILM removal.²⁶ This makes the removal of ILM unfavourable for the outcome of ERM surgery. Previous work has revealed that the best-corrected visual acuity was impaired in eyes that had ICG-assisted ERM peeling compared with a control group with no ICG.²⁷ Retention of dye on the retina of up to 9 months after surgery has been demonstrated by scanning laser ophthalmoscope.²⁸ This may cause delayed photochemical damage to the RPE cells. Toxic effects on RPE cells have also been demonstrated in rat eyes and human donor eyes.^{29,30} This may be due to the hypo-osmolarity of solvent (water and balanced saline solution).³¹ In contrast, a recent pilot study provides evidence that peeling of the ILM during ERM surgery may result in a better final visual outcome. The visual acuity was better and recurrence was lower in the group with ILM peeling during surgery compared with a group who did not have ILM peeling.^{32,33} It has been further suggested that ILM peeling up to the vascular arcade may prevent recurrence of symptomatic ERM.³⁴ If ICG is going to be



Fig 4. A syringe of trypan blue dye

used, the minimal effective concentration should be used with a minimal period of endoillumination.

Infracyanine green–assisted peeling

Infracyanine green is a green dye that stains the ILM in a way similar to ICG. The difference is the solvent that is 5% glucose solution and thus iso-osmotic. As the hypo-osmolarity of ICG is suspected to be responsible for RPE damage, infracyanine green may offer a safer alternative. Its staining properties are nonetheless inconsistent and it is not in wide use.³⁵ More studies of its staining properties are warranted before its toxicity and potential benefits over ICG can be determined.

Trypan blue–assisted peeling

Trypan blue (TB) is a blue stain that has been used to stain corneal epithelium and the anterior capsule of the lens (Fig 4). No toxicity has been observed after 8 years following its use in patients who had 0.1% TB-assisted anterior chamber surgery and capsulorhexis in cataract surgery. It has been in use for only a short period of time in vitreoretinal surgery.¹⁵⁻¹⁸ No signs of toxicity have been observed up to 1 year after ERM surgery assisted by 0.06% TB staining.¹⁷ A 0.06% concentration does not provide satisfactory staining in all cases and a higher concentration, 0.2%, gives a more useful bluish discoloration that facilitates surgery.¹⁸ The stain not only makes the ERM more easily identified, but enables a more complete removal of the membrane. The area of ERM is usually larger than that estimated ophthalmoscopically. With the stain, a larger area of the membrane can be identified and removed (Fig 5).¹⁵ This is especially true for the mature ERM that are more well-stained than fresh, immature membranes.¹⁵ For grade 1 ERM, ICG staining may give a better visualisation than TB staining.¹⁶ There are few data on the toxicity of TB. No toxicity has been shown in human eyes exposed to TB of up to a concentration of 0.3% for 5 minutes.³⁶ In rabbit eyes, prolonged exposure to 0.06% concentration under light showed no microscopic damage of RPE cells of up to 1 month. Nonetheless a higher concentration of 0.2% was associated with marked damage after 1 month in the lower quadrant of the retina of rabbit eyes.³⁷ More

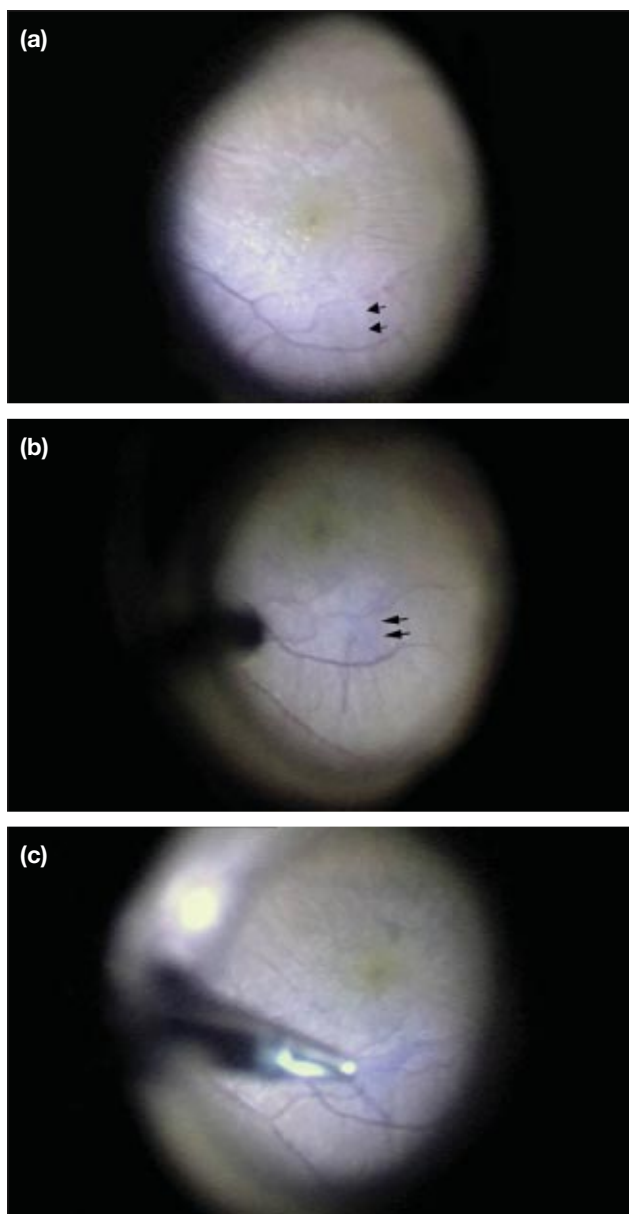


Fig 5. Intra-operative photographs of trypan blue–assisted grade 2 epiretinal membrane (ERM) surgery

(a) Before staining of the ERM, an edge can be seen on the ERM where peeling could be initiated (arrows). The overall extent of ERM was not clearly visible; (b) after staining of the ERM with trypan blue 0.06% solution, the edge of the ERM (arrows) and overall extent of the ERM are clearly seen; (c) the stained ERM was peeled with an Eckardt end-gripping forceps

studies are needed to determine the safety of TB in vitreoretinal surgery.

Double staining

A double staining technique has been developed.^{6,38} After vitrectomy, TB solution is used to stain the ERM. After peeling of the ERM, ILM is stained by ICG and peeled off (Fig 6). These two dyes are complementary, each having a different affinity for ERM and ILM, respectively. This method is an alternative to ‘negative staining’ by ICG or infracyanine

green alone. The membranes that are needed to be removed are stained in turn to improve visualisation. The benefits to anatomical and functional outcomes are yet to be defined.

Complications

Epiretinal membrane peeling is generally a safe operation and complications are few. Intra-operative complications include vitreous haemorrhage, retinal petechiae, retinal surface damage, and peripheral iatrogenic retinal breaks. Most can be successfully managed if promptly identified intra-operatively.^{21,39} Postoperative complications include the recurrence of ERM, accelerated nuclear sclerosis of crystalline lens, retinal detachment, and visual field disturbance.

The most common complication, occurring in 12% to 68% of cases, is accelerated nuclear sclerosis of crystalline lens.³⁹⁻⁴¹ This accelerated cataract is operable and the final vision should not be affected.³⁹ Recurrence occurs in 3% to 12%.^{41,42} It occurs less often in idiopathic ERM (<5% of cases) but more often in patients younger than 40 years or with secondary ERM associated with trauma or inflammatory disease.⁴³

Retinal detachment occurs in 3% to 14%.^{39,41} Those developing within 1 month postoperatively may be related to intra-operative retinal breaks. Those that develop after a few months are more often associated with residual vitreoretinal traction due to incomplete removal. Both can affect the final functional outcome.^{39,44} Careful inspection of the peripheral retina must be performed intra-operatively to search for iatrogenic retinal breaks.

Outcome

After surgery, vision is improved in most eyes but complete normalisation of visual acuity is rare.^{41,45} Similarly, the appearance of the retina tends to return to normal but not completely: 60% to 87% of eyes improve by 2 Snellen lines. The improvement continues for more than 6 months and the mean time to achieve best final vision is about 1 year.^{40,46} Prognostic factors associated with the visual outcome include preoperative visual acuity, duration of symptoms prior to surgery, preoperative lens status, intra-operative complications, aetiology, and the patient’s age.^{40,41,43,46} Eyes with worse preoperative vision demonstrate greater improvement following surgery. Ultimately though, the final vision is better in eyes with better preoperative visual acuity. Eyes with a longer history

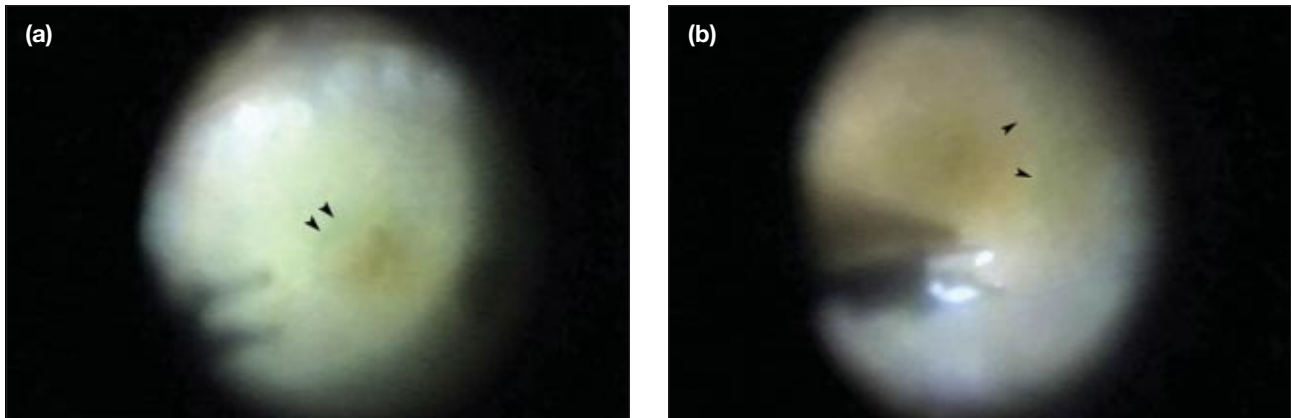


Fig 6. Intra-operative photographs of dye-assisted grade 3 epiretinal membrane (ERM) surgery

(a) After ERM removal, indocyanine green (ICG) 0.1% solution was injected over the disc, then the macula with the infusion temporarily stopped to stain the internal limiting membrane (ILM) [arrowheads]; (b) the ICG-stained ILM was peeled with Eckardt end-gripping forceps; ICG provides good contrast between areas of retina where ILM is removed or not (arrowheads)

of blurred vision have poorer visual acuity post-operatively and less improvement in vision. This may be due to the longer traction damage on the retina by the ERM.⁴⁵ Patients with good vision of the unaffected eye have a better functional outcome and higher subjective satisfaction.⁴⁷ Young patients and those with secondary ERM have more recurrences, thus final outcome is usually less satisfactory.^{41,43}

Conclusions

Epiretinal membrane is a common problem in the elderly. The most important symptoms are impaired visual acuity and metamorphopsia. The severity of the two symptoms can be conveniently measured and documented by Snellen chart and Amsler grid as well as M-charts, respectively. Surgical removal of the ERM is the mainstay of treatment. Several methods of removal have been described although the preferred one has not been established. Subtotal vitrectomy followed by removal of the membrane with or without staining is a widely accepted standard procedure. Non-vitrectomising surgery is a relatively new concept in ERM surgery. Initial results are encouraging with less postoperative nuclear sclerosis. Combined cataract and ERM surgery is another option for selected patients with concurrent cataract. Three dyes—0.125% ICG, 0.5% infracyanine green, and 0.2% TB—have been used to assist with equal effect to visualise the membrane. Toxicities of these three dyes should be evaluated by further studies. A double-staining technique using TB and ICG has been suggested to improve intra-operative visualisation but favourable results have yet to be demonstrated. Internal limiting membrane removal remains controversial in ERM surgery because of the conflicting results. Peeling of the ILM up to the vascular arcade may lower the recur-

rence rate. Before the end of surgery, utmost care is needed to inspect the periphery of the retina because intra-operative retinal breaks can precipitate retinal detachment that will compromise the final functional outcome. Postoperative follow-up of the patient should include close monitoring for recurrence of the ERM and postoperative complications, such as nuclear sclerosis, retinal detachment, and visual field disturbance. The unaffected eye should also be checked because bilateral involvement with ERM is common. Measurements of visual acuity and degree of metamorphopsia provide accurate and convenient indicators of functional outcome.

References

1. Mitchell P, Smith W, Chey T, Wang JJ, Chang A. Prevalence and associations of epiretinal membranes. The Blue Mountains Eye Study, Australia. *Ophthalmology* 1997;104:1033-40.
2. Fraser-Bell S, Guzowski M, Rochtchina E, Wang JJ, Mitchell P. Five-year cumulative incidence and progression of epiretinal membranes: the Blue Mountains Eye Study. *Ophthalmology* 2003;110:34-40.
3. Miller B. Epiretinal macular membranes: pathogenesis and treatment. *Dev Ophthalmol* 1997;29:61-3.
4. Appiah AP, Hirose T, Kado M. A review of 324 cases of idiopathic premacular gliosis. *Am J Ophthalmol* 1988;106:533-5.
5. Tadayoni R, Paques M, Massin P, Mouki-Benani S, Mikol J, Gaudric A. Dissociated optic nerve fiber layer appearance of the fundus after idiopathic epiretinal membrane removal. *Ophthalmology* 2001;108:2279-83.
6. Kwok AK, Lai TY, Yew DT, Li WW. Internal limiting membrane staining with various concentrations of indocyanine green dye under air in macular surgeries. *Am J Ophthalmol* 2003;136:223-30.
7. Suzuki T, Terasaki H, Niwa T, Mori M, Kondo M, Miyake Y. Optical coherence tomography and focal macular electroretinogram in eyes with epiretinal membrane and macular pseudohole. *Am J Ophthalmol* 2003;136:62-7.
8. Matsumoto C, Arimura E, Okuyama S, Takada S, Hashimoto S, Shimomura Y. Quantification of metamorphopsia in patients with epiretinal membranes. *Invest Ophthalmol Vis*

- Sci 2003;44:4012-6.
9. Kadonosono K, Itoh N, Uchio E, Nakamura S, Ohno S. Staining of internal limiting membrane in macular hole surgery. *Arch Ophthalmol* 2000;118:1116-8.
 10. Kwok AK, Li WW, Pang CP, et al. Indocyanine green staining and removal of internal limiting membrane in macular hole surgery: histology and outcome. *Am J Ophthalmol* 2001;132:178-83.
 11. Kwok AK, Lai TY, Chan WM, Woo DC. Indocyanine green assisted retinal internal limiting membrane removal in stage 3 or 4 macular hole surgery. *Br J Ophthalmol* 2003;87:71-4.
 12. Kwok AK, Lai TY, Yuen KS, Tam BS, Wong VW. Macular hole surgery with or without indocyanine green stained internal limiting membrane peeling. *Clin Experiment Ophthalmol* 2003;31:470-5.
 13. Kwok AK, Lai TY. Internal limiting membrane removal in macular hole surgery for severely myopic eyes: a case-control study. *Br J Ophthalmol* 2003;87:885-9.
 14. Kusaka S, Hayashi N, Ohji M, Hayashi A, Kamei M, Tano Y. Indocyanine green facilitates removal of epiretinal and internal limiting membranes in myopic eyes with retinal detachment. *Am J Ophthalmol* 2001;131:388-90.
 15. Feron EJ, Veckeneer M, Parys-Van Ginderdeuren R, Van Lommel A, Melles GR, Stalmans P. Trypan blue staining of epiretinal membranes in proliferative vitreoretinopathy. *Arch Ophthalmol* 2002;120:141-4.
 16. Kwok AK, Lai TY, Li WW, Yew DT, Wong VW. Trypan blue- and indocyanine green-assisted epiretinal membrane surgery: clinical and histopathological studies. *Eye* 2004;18:882-8.
 17. Perrier M, Sebag M. Epiretinal membrane surgery assisted by trypan blue. *Am J Ophthalmol* 2003;135:909-11.
 18. Teba FA, Mohr A, Eckardt C, et al. Trypan blue staining in vitreoretinal surgery. *Ophthalmology* 2003;110:2409-12.
 19. Demetriades AM, Gottsch JD, Thomsen R, et al. Combined phacoemulsification, intraocular lens implantation, and vitrectomy for eyes with coexisting cataract and vitreoretinal pathology. *Am J Ophthalmol* 2003;135:291-6.
 20. Saito Y, Lewis JM, Park I, et al. Nonvitrectomizing vitreous surgery: a strategy to prevent postoperative nuclear sclerosis. *Ophthalmology* 1999;106:1541-5.
 21. Charles S. Techniques and tools for dissection of epiretinal membranes. *Graefes Arch Clin Exp Ophthalmol* 2003;241:347-52.
 22. Sakamoto H, Yamanaka I, Kubota T, Ishibashi T. Indocyanine green-assisted peeling of the epiretinal membrane in proliferative vitreoretinopathy. *Graefes Arch Clin Exp Ophthalmol* 2003;241:204-7.
 23. Yam HF, Kwok AK, Chan KP, et al. Effect of indocyanine green and illumination on gene expression in human retinal pigment epithelial cells. *Invest Ophthalmol Vis Sci* 2003;44:370-7.
 24. Kwok AK, Lai TY, Yeung CK, Yeung YS, Li WW, Chiang SW. The effects of indocyanine green and endoillumination on rabbit retina: an electroretinographic and histological study. *Br J Ophthalmol* 2005;89:897-900.
 25. Sivalingam A, Eagle RC Jr, Duker JS, et al. Visual prognosis correlated with the presence of internal-limiting membrane in histopathologic specimens obtained from epiretinal membrane surgery. *Ophthalmology* 1990;97:1549-52.
 26. Mittleman D, Green WR, Michels RG, de la Cruz Z. Clinicopathologic correlation of an eye after surgical removal of an epiretinal membrane. *Retina* 1989;9:143-7.
 27. Haritoglou C, Gandorfer A, Gass CA, Schaumberger M, Ulbig MW, Kampik A. The effect of indocyanine-green on functional outcome of macular pucker surgery. *Am J Ophthalmol* 2003;135:328-37.
 28. Ashikari M, Ozeki H, Tomida K, Sakurai E, Tamai K, Ogura Y. Retention of dye after indocyanine green-assisted internal limiting membrane peeling. *Am J Ophthalmol* 2003;136:172-4.
 29. Enaida H, Sakamoto T, Hisatomi T, Goto Y, Ishibashi T. Morphological and functional damage of the retina caused by intravitreal indocyanine green in rat eyes. *Graefes Arch Clin Exp Ophthalmol* 2002;240:209-13.
 30. Gandorfer A, Haritoglou C, Gandorfer A, Kampik A. Retinal damage from indocyanine green in experimental macular surgery. *Invest Ophthalmol Vis Sci* 2003;44:316-23.
 31. Stalmans P, Van Aken EH, Veckeneer M, Feron EJ, Stalmans I. Toxic effect of indocyanine green on retinal pigment epithelium related to osmotic effects of the solvent. *Am J Ophthalmol* 2002;134:282-5.
 32. Park DW, Dugel PU, Garda J, et al. Macular pucker removal with and without internal limiting membrane peeling: pilot study. *Ophthalmology* 2003;110:62-4.
 33. Kwok AK, Lai TY, Yuen KS. Epiretinal membrane surgery with or without internal limiting membrane peeling. *Clin Experiment Ophthalmol* 2005;33:379-85.
 34. Kwok AK, Lai TY, Li WW, Woo DC, Chan NR. Indocyanine green-assisted internal limiting membrane removal in epiretinal membrane surgery: a clinical and histologic study. *Am J Ophthalmol* 2004;138:194-9.
 35. Ullern M, Roman S, Dhalluin JF, et al. Contribution of intravitreal infracyanine green to macular hole and epimacular membrane surgery: preliminary study [in French]. *J Fr Ophthalmol* 2002;25:915-20.
 36. Stalmans P, Van Aken EH, Melles G, Veckeneer M, Feron EJ, Stalmans I. Trypan blue not toxic for retinal pigment epithelium in vitro. *Am J Ophthalmol* 2003;135:234-6.
 37. Veckeneer M, van Overdam K, Monzer J, et al. Ocular toxicity study of trypan blue injected into the vitreous cavity of rabbit eyes. *Graefes Arch Clin Exp Ophthalmol* 2001;239:698-704.
 38. Stalmans P, Feron EJ, Parys-Van Ginderdeuren R, Van Lommel A, Melles GR, Veckeneer M. Double vital staining using trypan blue and infracyanine green in macular pucker surgery. *Br J Ophthalmol* 2003;87:713-6.
 39. Donati G, Kapetanios AD, Pournaras CJ. Complications of surgery for epiretinal membranes. *Graefes Arch Clin Exp Ophthalmol* 1998;236:739-46.
 40. Pesin SR, Olk RJ, Grand MG, et al. Vitrectomy for premacular fibroplasia. Prognostic factors, long-term follow-up, and time course of visual improvement. *Ophthalmology* 1991;98:1109-14.
 41. Margherio RR, Cox MS Jr, Trese MT, Murphy PL, Johnson J, Minor LA. Removal of epimacular membranes. *Ophthalmology* 1985;92:1075-83.
 42. Grewing R, Mester U. Results of surgery for epiretinal membranes and their recurrences. *Br J Ophthalmol* 1996;80:323-6.
 43. Banach MJ, Hassan TS, Cox MS, et al. Clinical course and surgical treatment of macular epiretinal membranes in young subjects. *Ophthalmology* 2001;108:23-6.
 44. Kim CY, Lee JH, Lee SJ, Koh HJ, Lee SC, Kwon OW. Visual field defect caused by nerve fiber layer damage associated with an internal limiting lamina defect after uneventful epiretinal membrane surgery. *Am J Ophthalmol* 2002;133:569-71.
 45. McDonald HR, Verre WP, Aaberg TM. Surgical management of idiopathic epiretinal membranes. *Ophthalmology* 1986;93:978-83.
 46. Rice TA, De Bustros S, Michels RG, Thompson JT, Debanne SM, Rowland DY. Prognostic factors in vitrectomy for epiretinal membranes of the macula. *Ophthalmology* 1986;93:602-10.
 47. Scott IU, Smiddy WE, Feuer W, Merikansky A. Vitreoretinal surgery outcomes: results of a patient satisfaction/functional status survey. *Ophthalmology* 1998;105:795-803.