

DWH Lee 李偉雄
YH Lam 林旭開
ACW Chan 陳志偉
SCS Chung 鍾尚志

Subfascial endoscopic perforator surgery for venous ulcers

以筋膜下內窺鏡穿透靜脈結紮術治療靜脈潰瘍

We report the treatment and outcomes of 12 patients who underwent subfascial endoscopic perforator surgery for severe chronic venous insufficiency and venous ulceration. All patients had received prior superficial venous ablative surgery and presented with incompetent perforating veins in the calf and persistent venous ulceration (lasting >10 years). Outcome measures included ulcer healing time, recurrence, clinical symptom, and disability scores. There was one wound complication after subfascial endoscopic perforator surgery. The cumulative ulcer healing rate was 25% at 3 months, 42% at 6 months, and 92% at 1 year. One patient developed ulcer recurrence at 12 months after surgery. The mean clinical score and disability score decreased from 13.00 (standard deviation, 2.26) to 4.83 (1.47) and 1.75 (0.45) to 0.50 (0.52), respectively ($P < 0.001$) after a median follow-up of 15.0 months (interquartile range, 12.0-21.5 months). Subfascial endoscopic perforator surgery was safe and effective in the treatment of patients with severe chronic venous insufficiency and venous ulceration caused by incompetent perforating veins in the calf.

本文報告12位患上慢性靜脈功能不全和靜脈性潰瘍的病者，在接受筋膜下內窺鏡穿透靜脈結紮術後，所達到的成效。所有病者之前已接受過淺靜脈部分切除，並有小腿肚靜脈閉塞不全，以及靜脈潰瘍達10年以上。我們利用病者康復所需的時間、復發情況、臨床症狀、及殘疾程度來量度治療結果。一位病者的傷口在手術後出現併發症。按累計，潰瘍的痊癒率在3個月後是25%，6個月後上升至42%，一年後達92%。手術12個月後，一位病者有潰瘍復發的跡象。跟進時間的中位數為15個月(四分位數間距為12.0至21.5個月)。跟進後發現臨床平均值從13.00(標準差，2.26)下降至4.83(標準差，1.47)，而殘疾程度則從1.75(標準差，0.45)降低至0.50(標準差，0.52)($P < 0.001$)。由此可見，筋膜下內窺鏡穿透靜脈結紮術能夠安全而有效地醫治由小腿肚靜脈閉塞不全引起的嚴重慢性靜脈功能不全和靜脈潰瘍。

Key words:

Endoscopy;
Recurrence;
Treatment outcome;
Varicose ulcer;
Venous insufficiency

關鍵詞：

內窺鏡；
復發；
治療結果；
靜脈曲張；
靜脈功能不全

Hong Kong Med J 2003;9:279-82

Department of Surgery, North District Hospital, 9 Po Kin Road, Hong Kong
DWH Lee, FRCS (Edin), FHKAM (Surgery)
ACW Chan, MD, FHKAM (Surgery)
Department of Surgery, The Chinese University of Hong Kong, Prince of Wales Hospital, Shatin, Hong Kong
YH Lam, FRCS (Edin), FHKAM (Surgery)
SCS Chung, MD, FHKAM (Surgery)

Correspondence to: Prof SCS Chung
(e-mail: sydneychung@cuhk.edu.hk)

Introduction

Subfascial endoscopic perforator surgery (SEPS) was recently introduced to replace conventional open surgery, such as Linton's procedure, in the management of chronic venous insufficiency (CVI).^{1,2} In comparative studies, SEPS was associated with fewer wound complications compared with Linton's procedure.^{3,4} Nonetheless, most reported series of patients undergoing SEPS recruited heterogeneous groups of patients who received various concomitant surgical procedures, such as superficial venous ablation.⁵⁻⁸ As a result, the exact role of SEPS in the management of CVI is controversial. In this study, we assessed the outcome of 12 patients who presented with persistent venous ulceration after previous superficial venous ablative surgery. All patients in the series underwent SEPS as the sole procedure in the management of venous ulcers at the Departments of Surgery, Prince of Wales Hospital and North District Hospital.

Subjects and methods

Between January 1998 and December 2001, we prospectively recruited patients with the following characteristics into the study:

- (1) they had previously received any superficial venous ablative surgery to treat varicose veins or CVI;
- (2) they presented with active or healed venous ulcers of class 5 or 6 of the CEAP system⁹—a system based on the clinical signs, aetiology, anatomical distribution, and pathophysiology of the lesions;
- (3) preoperatively, they had incompetent perforating veins in the calf or deep venous reflux, no superficial venous reflux, and no evidence of deep vein obstruction according to colour-flow duplex sonography;
- (4) they had an ankle-brachial index of more than 0.8 according to non-invasive vascular laboratory tests (ie no co-existing peripheral artery occlusive diseases); and
- (5) they had ulcer biopsy results that were negative for malignancy.

While awaiting SEPS, all patients received wound care from nurse specialists and wore single-layer elastic stockings prescribed by occupational therapists. Postoperatively, all patients were given the single-layer elastic stockings to wear until the first postoperative visit at 2 weeks after surgery. Patients with unhealed ulcers continued to receive wound care and were assessed by both the surgeons and occupational therapists. All patients were then followed up at 3-month intervals.

The primary outcome measure was ulcer healing and recurrence. In addition, we evaluated the clinical outcome by using a clinical scoring system proposed by the Consensus Committee of the American Venous Forum on Chronic Venous Disease.⁹

Surgical technique

Subfascial endoscopic perforator surgery was performed under general or regional anaesthesia. We gave a single dose of intravenous antibiotics for prophylaxis at induction for all patients. The affected limb was first exsanguinated using the rollover technique, and then a pneumatic tourniquet was applied at the mid-thigh to establish a bloodless operative field. A 1.5- to 2-cm long single-stab incision was made at the medial side of the affected calf below the knee. The subfascial plane was established with finger dissection and maintained with carbon dioxide gas insufflation at a pressure of 10 to 12 mm Hg.

We used the SEPS operating telescope (Olympus SEPS Endoscope; Olympus, Tokyo, Japan) to perform the procedure; the telescope has a lifting handle and a 5-mm operating channel through which the operating instruments are inserted. We used a 5-mm clamp coagulator ultrasonic scalpel (Autosonix system; Autosuture Company, Connecticut, US) to coagulate and transect perforating veins under direct endoscopic vision.¹⁰ We identified and transected most perforating veins in the medial calf, such as Cockett II, III, and paratibial perforating veins. In difficult areas, such as Cockett I perforating veins, separate incisions were sometimes necessary to ligate the perforators.

At the end of the procedure, a pressure dressing was applied to the limb; after 24 hours, it was changed to the single-layer stocking. Patients were discharged when they fulfilled all the following criteria:

- (1) satisfactory pain control was achieved with oral analgesics;
- (2) they could walk independently; and
- (3) assessment made by nurse specialists and occupational therapists was satisfactory.

Results

During the 4-year study period, we recruited a total of 12 patients: nine men and three women. The median age was 60 years (interquartile range [IQR], 41-68 years). Ten patients had previously undergone saphenofemoral junction ligation and stripping, as well as multiple stab incisions for calf vein avulsions, in different institutions. Two patients had previously undergone only saphenofemoral junction ligation and stripping. All patients had ulcers at the time of presentation. Nine patients presented with active ulcers, whereas three presented with healing ulcers (with some granulation tissue at the base of ulcer). The majority of patients (75%) had had symptoms of ulceration for more than 10 years before this presentation. The median maximal diameter of the ulcer was 3 cm (IQR, 2-4 cm). Seventy-five percent of the cases were operated on under spinal anaesthesia. The median operating time was 40 minutes (IQR, 35-50 minutes). The median number of perforating veins transected during surgery was 6.00 (IQR, 4.25-7.00). Postoperatively, the median number of doses of oral analgesics was 2.50 (IQR, 0.50-4.75). One patient developed wound infection and required wound-dressing care. There were no other complications in this series.

The median hospital stay was 3.50 days (IQR, 2.25-5.00 days), and the median time that patients needed to resume normal daily activity was 7.0 days (IQR, 5.0-11.5 days). The cumulative ulcer healing rate after SEPS was 25% at 3 months, 42% at 6 months, and 92% at 1 year (Fig) and the

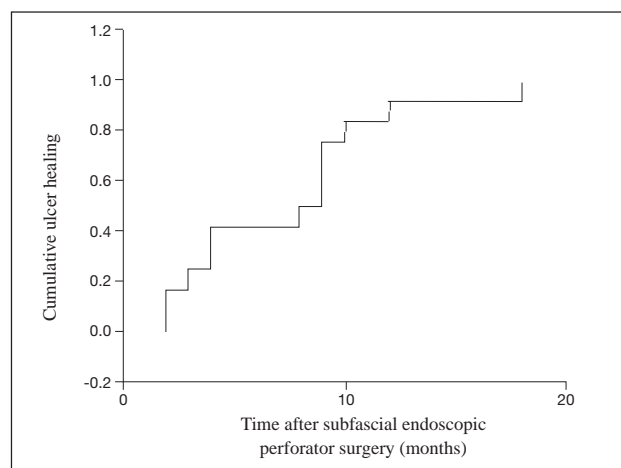


Fig. Cumulative ulcer healing after subfascial endoscopic perforator surgery

Table. Clinical and disability scores of patients with venous ulcers (n=12)

Characteristic (score definitions)	Preoperative score Mean (SD)	Postoperative score Mean (SD)
Pain (0=none; 1=moderate, not requiring analgesics; 2=severe, requiring analgesics)	1.83 (0.39)	0.58 (0.67)
Oedema (0=none; 1=mild/moderate; 2=severe)	1.50 (0.67)	0.92 (0.51)
Venous claudication (0=none; 1=mild/moderate; 2=severe)	0.25 (0.45)	0.25 (0.62)
Pigmentation (0=none; 1=localised; 2=extensive)	1.67 (0.49)	1.00 (0.60)
Lipodermatosclerosis (0=none; 1=localised; 2=severe)	1.83 (0.39)	1.00 (0.00)
Ulcer size (0=none; 1=less than 2 cm; 2=more than 2 cm)	1.58 (0.51)	0.25 (0.45)
Ulcer duration (0=none; 1=less than 3 months; 2=more than 3 months)	1.83 (0.39)	0.50 (0.52)
Ulcer recurrence (0=none; 1=once; 2=more than once)	1.33 (0.63)	0.08 (0.29)
Number of ulcers (0=none; 1=one; 2=multiple)	1.17 (0.39)	0.17 (0.39)
Total score (range, 0-18)	13.00 (2.26)	4.83 (1.47)*
Disability score (0=asymptomatic; 1=symptomatic, can function without supporting device; 2=can work 8 hours a day with supporting device; 3=unable to work even with supporting device)	1.75 (0.45)	0.50 (0.52)*

* Difference between preoperative and postoperative scores, $P < 0.001$ (Wilcoxon signed rank test)

median time for healing was 8.5 months. Ulceration recurred in one patient at 12 months after surgery. Duplex scanning in this patient did not reveal any residual perforating vein in the calf. After a median follow-up duration of 15.0 months (IQR, 12.0-21.5 months), the mean clinical score and disability score decreased from 13.00 (standard deviation, 2.26) to 4.83 (1.47) and 1.75 (0.45) to 0.50 (0.52), respectively ($P < 0.001$, Wilcoxon signed rank test) [Table].

Discussion

Medical and compressive therapies used to be common primary treatment modalities for patients with CVI and venous ulcers, but they usually required a prolonged period of non-ambulation.¹¹ As a result, non-compliance to these conservative treatments was not uncommon, and patients often sought surgical treatment. Traditional open surgery such as Linton's procedure¹² required a long incision over areas of compromised skin, thereby causing significant wound complications. Subfascial endoscopic perforator surgery was introduced in the 1980s to treat CVI.¹³ Because only a small stab incision was required for the insertion of the endoscope, subsequent wound complications occurred much less commonly than they did with open surgery.^{3,4} Nevertheless, the exact role of SEPS in the management of CVI was less evident, partly because most reported series were heterogeneous groups of patients with different degrees of CVI who received different concomitant surgical treatments.⁵⁻⁸ For example, saphenous vein ablation was often performed as a concomitant procedure. In this series, we aimed to evaluate the sole effect of SEPS on venous ulcer healing by recruiting a homogeneous group of patients

with persistent CVI who had received prior surgery for the superficial venous pathology. Most patients had had an ulcer that had lasted for more than 10 years, yet 92% of these ulcers healed within 1 year after SEPS. This result compared favourably to those described in most reported series, but the median time needed for healing was longer.^{5-8,14} One explanation is that we recruited the most severe CVI cases in this series; hence, the larger ulcers might have taken a longer time to heal. Nonetheless, ulceration recurred in only one limb, at 12 months after SEPS. In addition, the clinical and disability scores improved significantly after a median follow-up duration of 15 months, which again compared favourably to the results from the North American Subfascial Endoscopic Perforator Surgery Registry.^{7,14} Our results strongly suggest that SEPS plays a significant role in patients with incompetent perforating veins in the calf as a cause of CVI and venous ulcers.

The majority of reported series have performed SEPS on an ambulatory surgery basis. The median hospital stay in this study was 3.5 days to allow for assessments to be performed by nurse specialists and occupational therapists. We believe that SEPS can be performed safely as day surgery after proper arrangement with other specialists and better patient education.

Conclusion

Our series has shown that SEPS is safe and feasible, and causes minimal morbidity in the treatment of patients with severe CVI and venous ulcers. The favourable ulcer healing rate and improvement in clinical symptoms suggest that

SEPS plays a considerable role in correcting the underlying pathology in CVI caused by incompetent perforating veins in the calf. While we are awaiting definitive answers by others from randomised trials, we believe that SEPS should be the surgical treatment of choice for patients with severe CVI and venous ulcers caused by incompetent perforating veins in the calf.

References

1. Bergan JJ, Murray J, Greason K. Subfascial endoscopic perforator vein surgery: a preliminary report. *Ann Vasc Surg* 1996;10:211-9.
2. Gloviczki P. Subfascial endoscopic perforator vein surgery: indications and results. *Vasc Med* 1999;4:173-80.
3. Pierik EG, van Urk H, Hop WC, Wittens CH. Endoscopic versus open subfascial division of incompetent perforating veins in the treatment of venous leg ulceration: a randomized trial. *J Vasc Surg* 1997;26:1049-54.
4. Stuart WP, Adam DJ, Bradbury AW, Ruckley CV. Subfascial endoscopic perforator surgery is associated with significantly less morbidity and shorter hospital stay than open operation (Linton's procedure). *Br J Surg* 1997;84:1364-5.
5. Sparks SR, Ballard JL, Bergan JJ, Killeen JD. Early benefits of subfascial endoscopic perforator surgery (SEPS) in healing venous ulcers. *Ann Vasc Surg* 1997;11:367-73.
6. Nelzen O. Prospective study of safety, patient satisfaction and leg ulcer healing following saphenous and subfascial endoscopic perforator surgery. *Br J Surg* 2000;87:86-91.
7. Gloviczki P, Bergan JJ, Menawat SS, et al. Safety, feasibility, and early efficacy of subfascial endoscopic perforator surgery: a preliminary report from the North American registry. *J Vasc Surg* 1997;25:94-105.
8. Lee DW, Chan AC, Lam YH, et al. Early clinical outcomes after subfascial endoscopic perforator surgery (SEPS) and saphenous vein surgery in chronic venous insufficiency. *Surg Endosc* 2001;15:737-40.
9. Porter JM, Moneta GL. Reporting standards in venous disease: an update. International Consensus Committee on Chronic Venous Disease. *J Vasc Surg* 1995;21:635-45.
10. Lee DW, Chan AC, Lam YH, et al. Subfascial endoscopic perforator vein surgery (SEPS) using the ultrasonic scalpel. *Surg Endosc* 2001;15:1491-3.
11. Fletcher A, Cullum N, Sheldon TA. A systematic review of compression treatment for venous leg ulcers. *BMJ* 1997;315:576-80.
12. Linton RR. The communicating veins of the lower leg and the operative technique for their ligation. *Ann Surg* 1938;107:582-93.
13. Hauer G, Bergan JJ, Werner A, Mitterhusen M, Nasralla F. Development of endoscopic dissection of perforating veins and fasciotomy for treatment of chronic venous insufficiency. *Ann Vasc Surg* 1999;13:357-64.
14. Gloviczki P, Bergan JJ, Rhodes JM, Canton LG, Harmsen S, Ilstrup DM. Mid-term results of endoscopic perforator vein interruption for chronic venous insufficiency: lessons learned from the North American subfascial endoscopic perforator surgery registry. The North American Study Group. *J Vasc Surg* 1999;29:489-502.