

R Kay 祁理治
 WY Lau 劉詠恩
 HK Ng 吳浩強
 YL Chan 陳宇亮
 DJ Lyon
 CA van Hasselt

Variant Creutzfeldt-Jakob disease in Hong Kong

香港的一宗非典型克雅二氏症

A 34-year-old Chinese woman who had lived in the United Kingdom in the 1980s was admitted to hospital in Hong Kong because of a 7-month history of progressive neurological deterioration. Initially, she complained of heartburn and paraesthesia of the hands and feet. She then developed slowness of speech and gait, and was noted to be forgetful and irritable. In January 2001, she was brought back to Hong Kong for treatment. On admission in May she was dysarthric, ataxic, and dystonic. Magnetic resonance imaging showed high signals in both thalami suggestive of variant Creutzfeldt-Jakob disease. Other investigations, including electroencephalogram and lumbar puncture, were unremarkable. A tonsil biopsy showed the presence of prions. This patient's presentation is typical of the variant Creutzfeldt-Jakob disease cases that have been reported since 1996. Because of her residential history, we conclude that this is an imported case from the United Kingdom.

Key words:

Creutzfeldt-Jakob syndrome;
Encephalopathy, bovine spongiform;
Great Britain;
Hong Kong;
Prions

關鍵詞：

克雅二氏症；
 腦病，牛海綿狀的；
 英國；
 香港；
 朊病毒

一名34歲華裔女病人因連續7個月呈現持續惡化的腦神經紊亂而被送入香港的一所醫院。病人於1980年代曾經在英國居住。病情開始時，病人感到胃灼熱，並且手腳有針刺感。漸漸地，病人說話開始遲鈍，步伐亦較緩慢，並且變得健忘和易怒。病人於2001年1月被帶返香港接受治療，於5月入住醫院時，發現病人發音有障礙，步態不穩，動作失調。磁共振成像術顯示兩邊的丘腦位置有明顯轉變的徵狀，證明病人可能患有非典型克雅二氏症。其他檢查包括用腦電描記術和腰椎穿刺都未發現有異常情況，而扁桃體活組織檢查卻發現有朊病毒的存在。這位病人的情況是自1996年以來曾經報告過的非典型克雅二氏症的典型病例。根據病人的居住紀錄，我們認為這是一宗經英國傳入香港的非典型克雅二氏症的病例。

HKMJ 2001;7:296-8

The Chinese University of Hong Kong,
 Prince of Wales Hospital, Shatin, Hong
 Kong:
 Department of Medicine and Therapeutics
 R Kay, MD, FRCP
 WY Lau, MB, ChB
 Department of Anatomical and Cellular
 Pathology
 HK Ng, MD, FRCPath
 Department of Diagnostic Radiology and
 Organ Imaging
 YL Chan, MB, FRCP
 Department of Microbiology
 DJ Lyon, MB, FRCPath
 Department of Surgery
 CA van Hasselt, MMed, FCS(SA)

Correspondence to: Prof R Kay

Introduction

Prion diseases are brain diseases caused by the accumulation in neurons of abnormal forms of a natural protein, designated prion protein.¹ Until recently, four human prion diseases were known: kuru, Creutzfeldt-Jakob disease (CJD), Gerstmann-Straussler-Scheinker syndrome, and fatal familial insomnia. The best known of these is CJD, a mainly sporadic disease, but one which may be inherited or acquired iatrogenically. In 1996, a new type of prion disease, now called variant CJD (vCJD), was identified in the UK. It soon became apparent that this disease was linked to the bovine spongiform encephalopathy (BSE) epidemic which affected cattle in that country in the 1980s. To date, approximately 100 cases of vCJD have been detected in the UK and continental Europe. We now report the first case of vCJD found in Asia, in a Chinese woman who had lived in the UK in the 1980s.

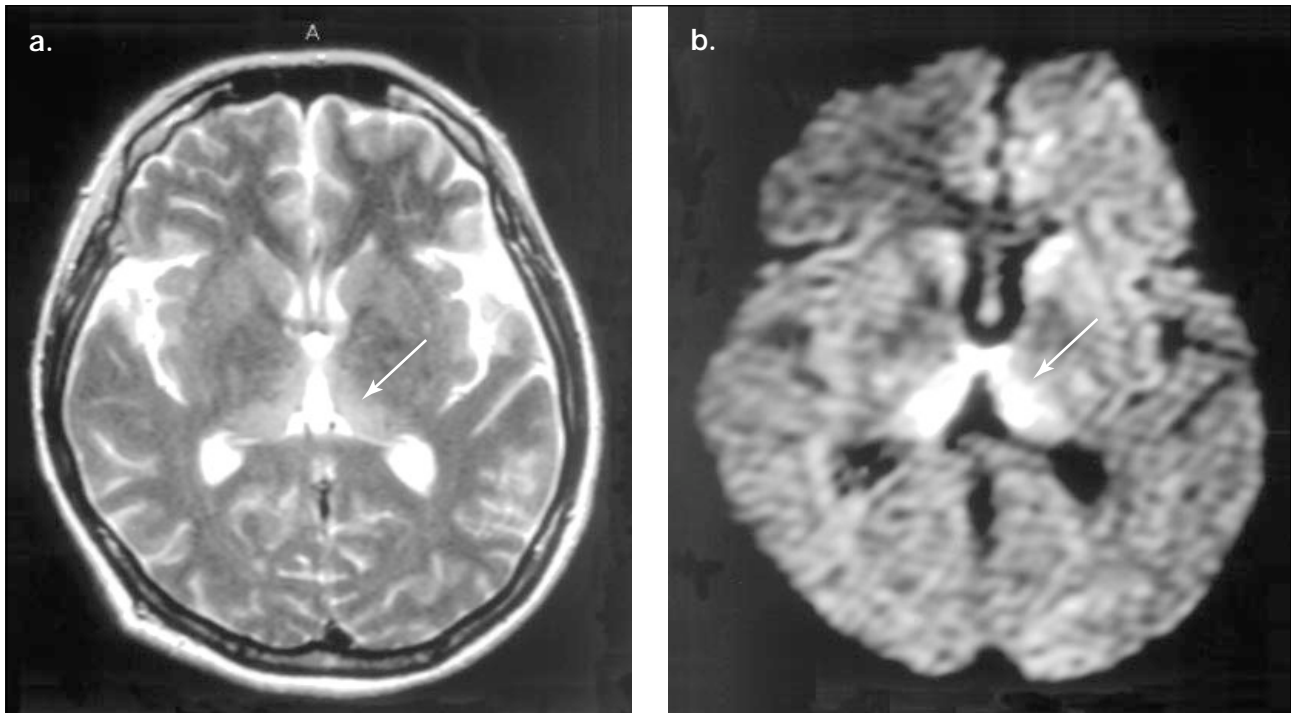


Fig 1. Magnetic resonance imaging of the brain

T2-weighted (a) and diffusion-weighted (b) scanning showing high signals in the pulvinar and dorsomedial nuclei (arrows) of both thalami

Case report

A Chinese woman, now aged 34 years, was a New Territories resident until 1983 when she moved to the UK. There she worked in a Chinese restaurant until 1992. Between 1992 and 1997, she returned to Hong Kong and worked as a saleswoman. In 1997, she returned to the UK once again and worked in a Chinese restaurant. Apart from a minor operation to remove a breast lump in 1996, her past health was good and she had never received or donated blood. She had no peculiar dietary preferences and was not particularly fond of beef.

In October 2000, the patient developed a burning sensation in her chest and back. This was diagnosed as heartburn, although at times the sensation also involved the hands and feet. She then became forgetful, being unable to remember certain telephone numbers and daily activities. Her speech was slow and her movements seemed stiff. In January 2001, she was brought back by her relatives to Hong Kong to seek medical advice. A psychiatrist was consulted who ordered a magnetic resonance imaging (MRI) of her brain in May 2001. This showed high signals in both thalami suggestive of vCJD, and she was referred immediately to the Prince of Wales Hospital. On admission, she was well nourished. She was disorientated and her speech was slurred. Her muscle tone was increased but she had full power. Her posture was dystonic and

her gait was ataxic. Routine blood tests, including caeruloplasmin level, were normal, as was the electroencephalogram. Repeat MRI showed a high signal in the pulvinar and dorsomedial nucleus of both thalami (Fig 1). Lumbar puncture showed normal cerebrospinal fluid, which was later found to contain the brain-specific protein 14-3-3.² A tonsil biopsy was performed and processed according to the guidelines drawn up by the Hospital Authority. This showed on immunostaining the presence of prions (Fig 2) which, on Western blot analysis, had a glycoform pattern characteristic of vCJD.

The patient continued to deteriorate after admission. After 6 weeks, she was no longer able to speak or walk.

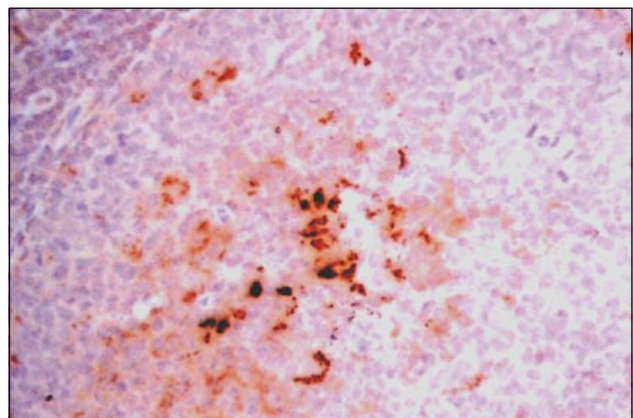


Fig 2. Tonsil biopsy: immunostaining with anti-prion antibodies show positive lymphoid cells and macrophages

She could recognise only her relatives and accept feeding by mouth.

Discussion

Creutzfeldt-Jakob disease was first described in the 1920s by two German neurologists who described a syndrome of “spastic pseudosclerosis: encephalomyelopathy with disseminated neurogenic lesions”.³ The disease is rare, affecting approximately one in a million people per year, and has a worldwide distribution. In Hong Kong, for instance, about 20 cases of CJD have been reported since 1996. The possibility that CJD was transmissible was suggested by the work of the Nobel neurologist Carlton Gajdusek who demonstrated that a similar disease, kuru, was transmitted through cannibalism among New Guinean natives. For a time, the infective agent was thought to be a ‘slow virus’, as the incubation period could last for decades. It was left to another Nobel neurologist, Stanley Prusiner, to suggest in 1982 that the infective agent was actually a protein (hence the term ‘prion’—proteinaceous infectious particle). A normal form of prion is present in all mammals although its function is unclear. The crucial difference between normal and abnormal forms of prion protein is that when the latter gets into a cell, it can convert normal prion protein molecules into abnormal ones, which are not broken down by enzymes. These abnormal molecules clump together to form amyloid plaques, which eventually lead to cell damage. The brain is perhaps especially vulnerable because neurons do not renew themselves.

The fact that two Nobel prizes were awarded to investigators of such a rare disease highlights the importance of their discoveries. The ‘third wave’ of this saga must be the demonstration of the potential devastation prions can cause by crossing the species barrier.⁴ For centuries, sheep have been known to suffer from a nervous system disease known as scrapie and, when British cattle became infected with BSE in large numbers in the 1980s, it was suggested that the practice of adding ruminant (sheep and cow) carcasses to animal feed was responsible for a cascade effect which led to the BSE epidemic. Since the ban on this feeding practice in 1988, the number of BSE cases has declined. Concerns about cross-species transmission led to the establishment of the National CJD Surveillance Unit in Edinburgh, Scotland. By 1996, it was clear that what is now called vCJD had emerged in the UK, most likely as a result of consumption of BSE-infected beef.

Variant CJD differs from classical CJD in several respects: patients are younger (average age of onset is before 30 years), symptoms at onset are more psychiatric than neurological (except for dysaesthesia), and the course of illness is longer. Pathologically, vCJD brains have more extensive plaque deposition throughout the cerebrum and cerebellum.

The patient in this report satisfied the criteria laid down by the Edinburgh Unit for the diagnosis of probable vCJD (only postmortem cases can be definite):

- (1) Progressive neuropsychiatric disorder, duration of illness of more than 6 months, absence of an alternative diagnosis, no history of potential iatrogenic exposure;
- (2) Early psychiatric symptoms, persistent painful sensory symptoms, ataxia, myoclonus or chorea or dystonia, dementia; and
- (3) Absence of triphasic periodic complexes typical of classical CJD on electroencephalogram, and presence of posterior thalamic high signals on MRI.

A tonsil biopsy is not required, but if found to be positive, can replace criteria 2 and 3.

Taking into account the patient’s residential history, we consider this to be a case of imported vCJD from the UK. Since BSE-infected beef might have been imported to Hong Kong during the 1980s, a person could also acquire vCJD without ever having lived in Europe.

Acknowledgements

We thank Dr R Knight, Dr D Collie, Prof J Ironside, and the staff of the National CJD Surveillance Unit, Edinburgh, UK, for their assistance and advice. The tests for protein 14-3-3 and Western blot analysis were performed in Edinburgh.

References

1. Prusiner SB. Shattuck lecture: neurodegenerative diseases and prions. *N Engl J Med* 2001;344:1516-26.
2. Green AJ, Thompson EJ, Stewart GE, et al. Use of 14-3-3 and other brain-specific proteins in CSF in the diagnosis of variant Creutzfeldt-Jakob disease. *J Neurol Neurosurg Psychiatry* 2001;70:744-8.
3. Walton J. *Brain’s diseases of the nervous system*. 9th ed. Oxford: Oxford University Press; 1985:379-80.
4. Johnson RT, Gibbs CJ Jr. Creutzfeldt-Jakob disease and related transmissible spongiform encephalopathies. *N Engl J Med* 1998;339:1994-2004.